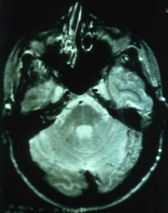


Zittern, Hörstörung,
amalgambedingtes ADHS- Syndrom
Amalgam in Zahnfächern und
Nasennebenhöhlen



MR T1W AXIAL C1-C2

TR: 450.00

TE: 12.00

FOV: 230.00

1.00

1.00

1.00

1.00

1.00

1.00

1.00

1.00

1.00

1.00

1.00

1.00

1.00

1.00

1.00

1.00

1.00

1.00

1.00

1.00

1.00

1.00

1.00

1.00

1.00

1.00

1.00

1.00

1.00

1.00

1.00

1.00

1.00

1.00

1.00

1.00

1.00

1.00

1.00

1.00

1.00

1.00

1.00

1.00

1.00

1.00

1.00

1.00

1.00

1.00

1.00

1.00



MR T1W AXIAL C1-C2

TR: 450.00

TE: 12.00

FOV: 230.00

1.00

1.00

1.00

1.00

1.00

1.00

1.00

1.00

1.00

1.00

1.00

1.00

1.00

1.00

1.00

1.00

1.00

1.00

1.00

1.00

1.00

1.00

1.00

